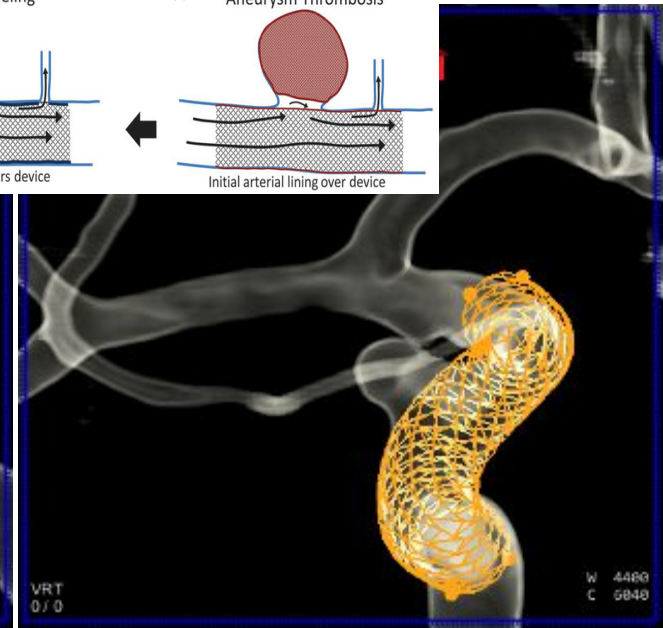
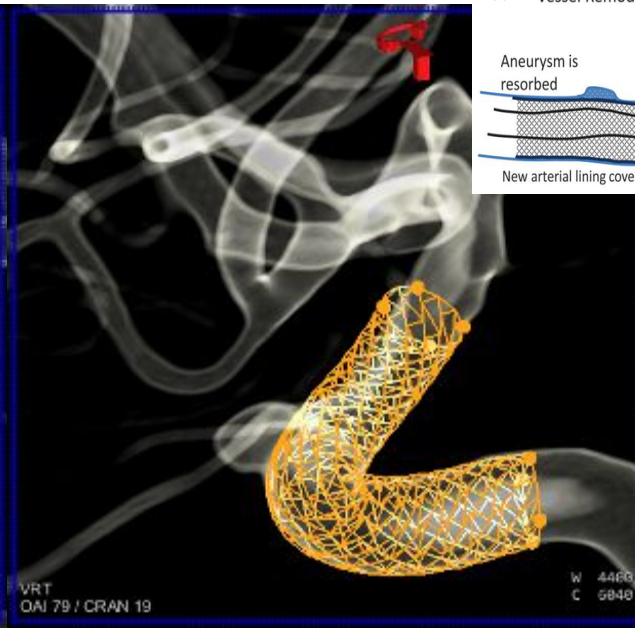
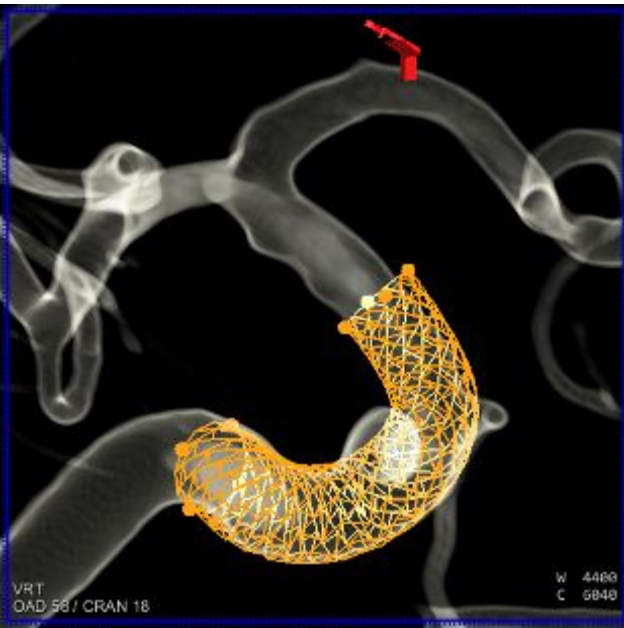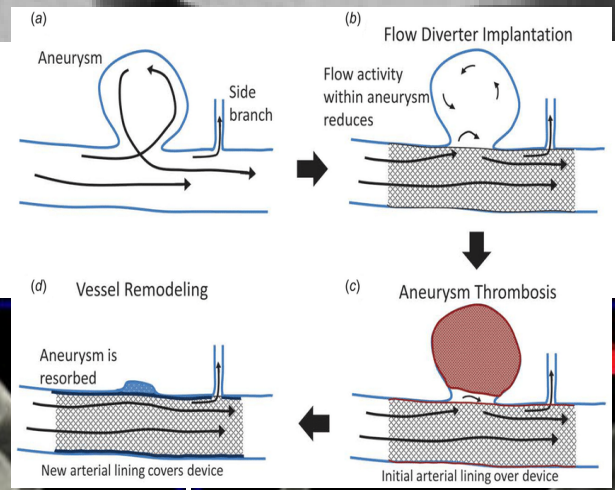
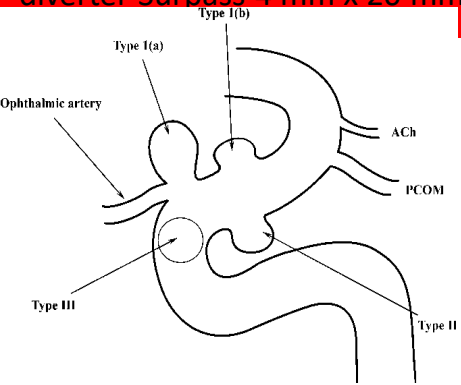
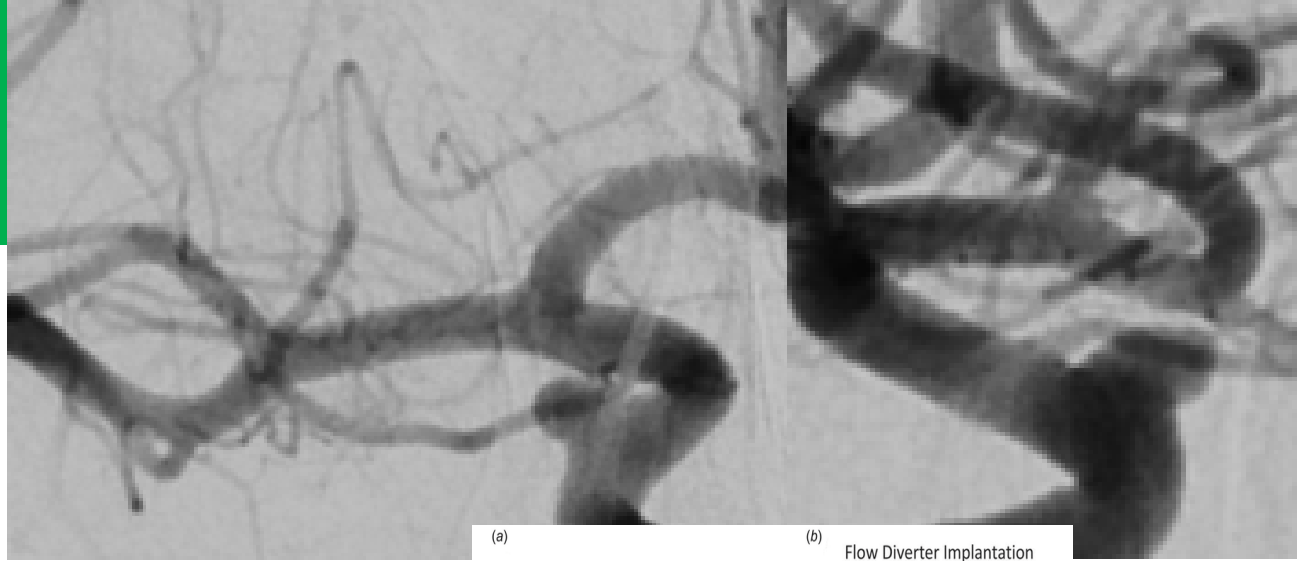


Aneurisma incidental paraoftálmico-cavernoso derecho.

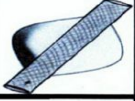

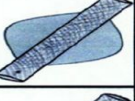
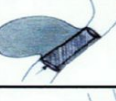


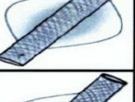
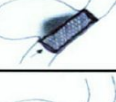
Tto con FD

Cefaleas.
 Aneurisma incidental.
 Angiografía cerebral 3 D.
 Tratamiento con stent flow diverter Surpass 4 mm x 20 mm.



Aneurisma incidental paraoftálmico-cavernoso derecho.

Tto con FD

		fusiform aneurysm	saccular aneurysm
arterial phase	Grade 0 early, coherent jet		
	Grade 1 patent		
venous phase	Grade 2 unsecured wall/dome		
	Grade 3 secured wall		
	Grade 4 occluded	